

12-1975

## Radionuclide Bone Imaging in the Evaluation of Prostatic Cancer

Daniel S. Marks

William R. Eyler

Follow this and additional works at: <https://scholarlycommons.henryford.com/hfhmedjournal>

 Part of the [Life Sciences Commons](#), [Medical Specialties Commons](#), and the [Public Health Commons](#)

### Recommended Citation

Marks, Daniel S. and Eyler, William R. (1975) "Radionuclide Bone Imaging in the Evaluation of Prostatic Cancer," *Henry Ford Hospital Medical Journal* : Vol. 23 : No. 4 , 161-168.

Available at: <https://scholarlycommons.henryford.com/hfhmedjournal/vol23/iss4/3>

This Article is brought to you for free and open access by Henry Ford Health System Scholarly Commons. It has been accepted for inclusion in Henry Ford Hospital Medical Journal by an authorized editor of Henry Ford Health System Scholarly Commons.

## Radionuclide Bone Imaging in the Evaluation of Prostatic Cancer

Daniel S. Marks, MD and William R. Eyer, MD\*

*Radionuclide bone imaging is a rapid, easily performed, noninvasive method for evaluation of skeletal disease in carcinoma of the prostate, or any other malignancy. In a significant number of cases, it may provide the only evidence of metastases and frequently demonstrates more widespread involvement than previously suspected. Thus, it may redirect the chosen course of therapy or localize sources of bone pain that are not radiographically apparent. Sixty-two percent of 42 patients studied were abnormal, of which 12% had no radiographic evidence of disease.*

For any patient harboring a malignant neoplasm, methods of determining the extent of disease are of great value in planning the best course of action. Among the procedures available today, radionuclide bone imaging is the most sensitive means of detecting skeletal extension of tumors. This report presents our experience with bone imaging in patients with cancer of the prostate.

Radionuclide bone imaging is dependent on bone production as a physiologic response to an injury or destructive process. Areas are sought of increased osteoblastic activity detected by display of increased radionuclide deposition. Even those lesions shown to be purely lytic on radiographs have been found microscopically to have a reactive front resulting in mixed destructive and productive areas.<sup>1-4</sup>

Unfortunately, no isotope of calcium is useful in clinical nuclear medicine, but isotopes of strontium and fluorine have been used in the recent past with accumulation of much useful data. These agents, while clinically more suitable than calcium, are also less than ideal because of their high gamma energies, inappropriate half-lives and cost. With the introduction of phosphate compounds labeled with <sup>99m</sup>Tc, bone imaging became possible as a screening examination in patients with malignancy.<sup>5</sup> The energy of <sup>99m</sup>Tc (140 KeV) is more efficiently detected by the sodium iodide crystals used

---

\*Department of Radiology

Address reprint requests to Dr. Marks at Henry Ford Hospital, 2799 West Grand Boulevard, Detroit, MI 48202

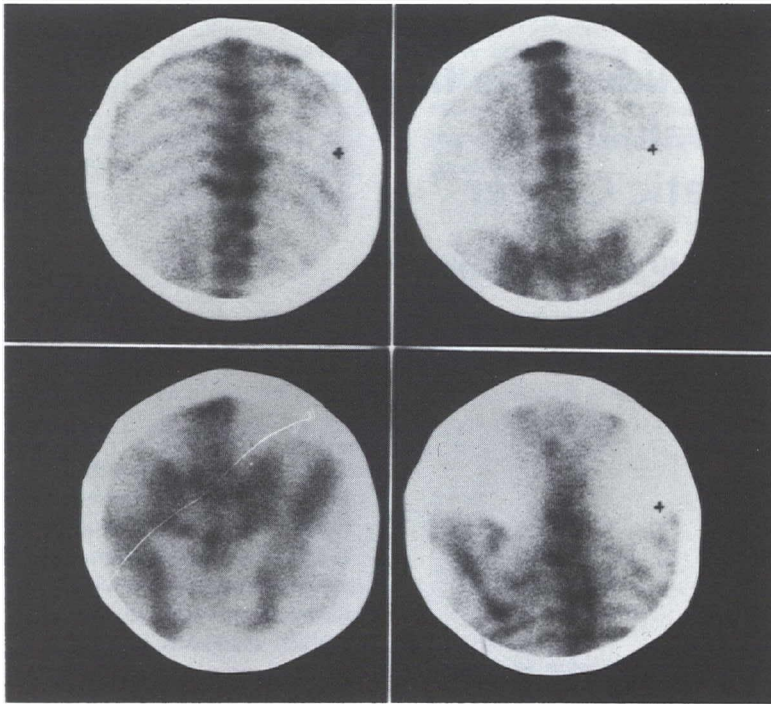


Figure 1a

Patient is a 79-year-old man with cancer of the prostate discovered six year previously, who now complains of back pain. Images show involvement of the pelvis, which was previously known, as well as uptake in the spine, left scapula, and several ribs. The patient's right side is to the reader's right (marked by a small cross on three of the views).

in modern scanners and gamma cameras, allowing for a marked increase in resolution and information density. Indeed, pedicles of the vertebrae are routinely shown on bone images made with a well adjusted gamma camera. Several studies<sup>4,6,7</sup> have clearly documented superior and improved lesion detection by Tc-phosphate compounds compared to <sup>85</sup>Sr and <sup>18</sup>F. No reactions to the injection of Tc-phosphate compounds have been reported,<sup>4</sup> and the radiation dose of 0.1-0.45 rads<sup>5</sup> allows for multiple studies, use in children and in non-neoplastic conditions.

### Methods

From January, 1974, through September, 1975, at Henry Ford Hospital, 42 patients with cancer of the prostate who had been

studied by bone imaging were reviewed. Most were newly discovered cases, although a few had been identified several months prior to bone imaging. One case (Figure 1) had been known for six years, but was initially evaluated by radionuclide study during this time; the case is included for illustrative purposes.

All patients received 15 mCi of <sup>99m</sup>Tc pyrophosphate prepared from commercially available kits. Gamma camera images were obtained three to four hours after intravenous injection of the radioagent. Comparison with radiographs was made at the time of interpretation. In most cases, the radiographs and radionuclide images were obtained within a few days of each other; in no case was the time interval between studies inappropriate. In one case of metastatic



## Radionuclide Bone Imaging

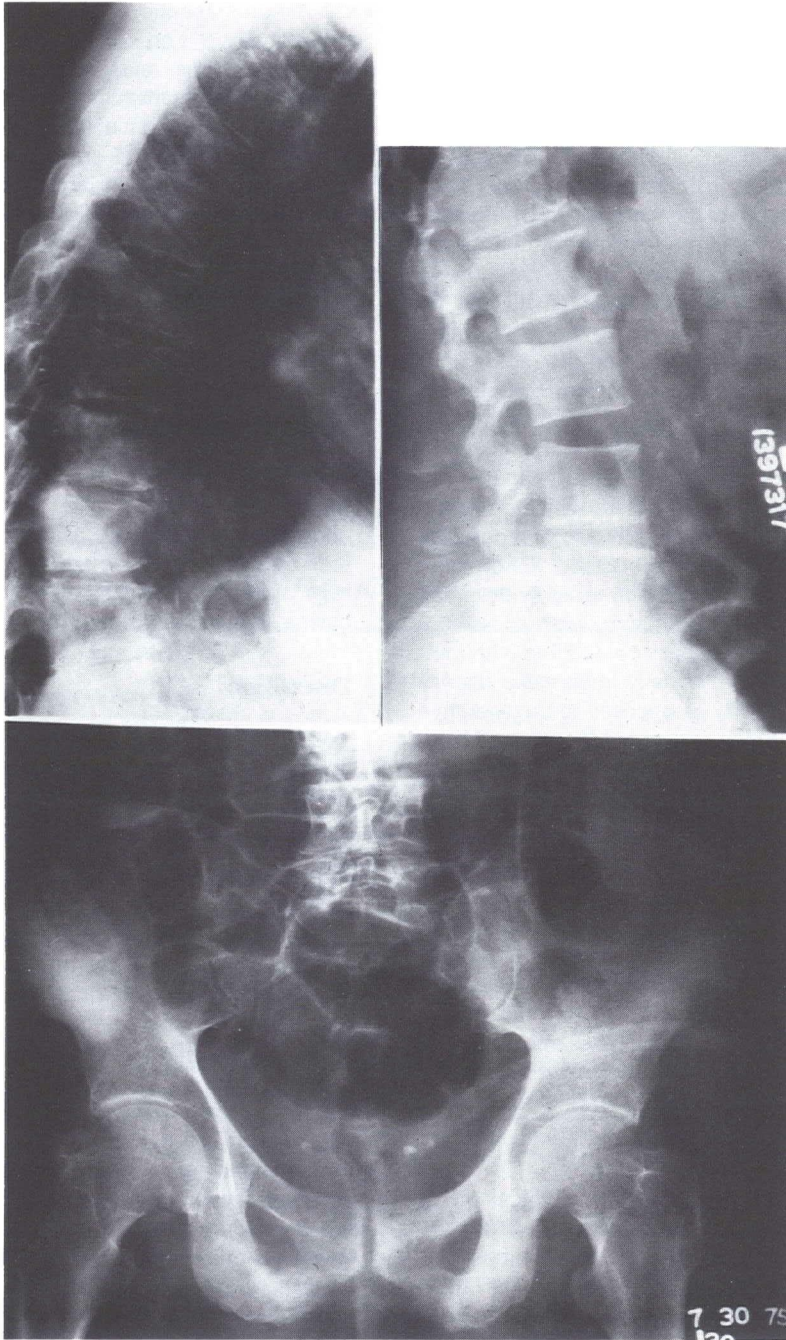


Figure 1b

Radiographs show osteoblastic involvement of the pelvis, but the mild degenerative change in the spine is not sufficient explanation for the abnormalities seen on the images; therefore, metastatic disease is more extensive than demonstrated radiographically.

## Marks and Eyler

disease, no radiographs were available for comparison.

Results are tabulated in Table I. A normal examination is defined as one with no areas of increased activity other than physiologic activity seen in large joints, the sacroiliac areas, the tips of the scapulae and the base of the skull. Abnormal studies not considered indicative of metastatic disease are those in which areas of increased activity can be explained by degenerative changes or other benign conditions seen on the radiographs (Table II). This list is far from complete as many non-neoplastic conditions can result in increased activity. Abnormal images suspicious for metastatic disease are those with one or two active areas for which no explanation can be seen on the radiographs. The typical pattern of metastatic abnormality (Figure 2) is that of numerous widespread areas of increased activity with or without radiographic changes compatible with metastatic disease. Usually, metastases display intense activity as opposed to degenerative disease which shows mildly increased activity in most cases. Any factor increasing bone mass or density can cause a "hot" area.

Sixteen patients (38%) had either normal studies or findings other than metastases. Twenty-six (62%) had positive studies of which eleven (26%) had suspicious findings, thirteen (31%) showed a typically metastatic pattern, and two patients (5%) had an initially normal study which became abnormal on a progress examination. This change, of course, is highly suspicious of metastatic disease.

The thirteen cases with a typical metastatic pattern on the radionuclide study are further analyzed in Table III. The most significant finding is that five patients (38%) had no metastases by radiography. Thus, the radionuclide bone image was the only evidence of the widespread nature of their disease. This represents 12% of the total number of patients included in this study. Such results would obviously preclude radi-

cal radiotherapeutic or surgical treatment. Additionally, it is now well known that 30% to 50% of bone mass must be removed before an abnormality can be seen on radiographs.<sup>1,8</sup> This amount of bone loss is equivalent to a lesion 1.0-1.5 cm in diameter.<sup>1</sup> In the axial skeleton, even larger lesions may be difficult to identify radiographically, especially since the age group concerned with prostatic malignancy frequently has co-existent degenerative disease. Detection of even very small lesions is made possible by the concentration of activity within them.<sup>9</sup> Also of note is the absence of any false negative results in our series. Other publications have reported low false negative results of 0-5%<sup>1,7,10,11</sup> using <sup>85</sup>Sr and <sup>18</sup>F. The figures should become even lower with the Tc-phosphate compounds. Abnormalities on scan frequently precede radiographic findings by several months and one author claims an interval of up to three years.<sup>3</sup>

## Discussion

Our results again emphasize the validity and value of bone imaging in cancer of the prostate. Several previous studies<sup>8,9,11,12,13</sup> have reported positive radionuclide images in 47% to 70% of patients examined for prostatic neoplasm. This correlates well with the 62% incidence of positive studies in this report. Additionally, it has now been shown that 19% to 30% of these patients will have abnormal images in the presence of normal radiographs.<sup>1,9,11,14</sup>

The patient who shows typical metastatic patterns, whether anticipated or not, does not present any significant dilemma as to further management; palliative therapy is indicated. Likewise, the patient with a normal study should present little problem (provided other studies are within normal limits); radical, curative therapy is to be considered.

What, then, is to be done with the suspicious group? If some other condition precludes curative surgery or radiotherapy, progress bone images should be obtained at

## Radionuclide Bone Imaging

**Table I**

| BONE IMAGES IN EARLY CANCER OF THE PROSTATE (TOTAL 42 STUDIES) |  |   |  |   |
|--|--|---|--|---|
| NORMAL   | ABNORMAL<br>NOT CONSIDERED<br>METASTATIC | ABNORMAL<br>SUSPICIOUS OF<br>METASTATIC DISEASE<br>(ONE OR TWO ABNORMAL<br>AREAS NOT EXPLAINED<br>ON RADIOGRAPHS) | ABNORMAL<br>PATTERN CONSISTENT<br>WITH METASTATIC<br>DISEASE | INITIALLY NORMAL<br>BECOMING ABNORMAL<br>ON PROGRESS STUDY<br>(SUSPICIOUS OF<br>METASTATIC DISEASE) |
| 9 (21%)  | 7 (17%)                                  | 11 (26%)  | 13 (31%)   | 2 (5%)  |
| TOTAL 16 (38%)   |  | TOTAL 26 (62%)  |  |   |

**Table II**

| CAUSES OF ABNORMALITIES NOT CONSIDERED AS METASTATIC |   |
|--|---|
| NON BONY UPTAKE                                      | 1 |
| ANKYLOSING SPONDYLITIS                               | 1 |
| TRAUMA   | 1 |
| DEGENERATIVE DISEASE                                 | 4 |

**Table III**

| ABNORMAL STUDIES CONSISTENT WITH METASTASES (13)  |                              |  |   |  |
|---|------------------------------|--|---|--|
| RADIOGRAPHS<br>NORMAL   | NO COMPARISON<br>RADIOGRAPHS | SAME LESIONS<br>SEEN ON BOTH<br>RADIOGRAPH<br>AND IMAGES | DISEASE MORE<br>EXTENSIVE ON<br>IMAGES THAN ON<br>RADIOGRAPHS | ABNORMAL<br>RADIOGRAPHS,<br>NORMAL<br>IMAGES |
| 5<br>(38%)<br><br>(12% of all studies)  | 1<br>(8%)                    | 2<br>(16%)   | 5<br>(38%)  | 0  |
| NOTE: OF THE TWO STUDIES WHICH BECAME ABNORMAL AFTER AN INITIALLY NORMAL IMAGE, ONE HAD NO CORRESPONDING RADIOGRAPHIC CHANGE AND ONE HAD MORE EXTENSIVE DISEASE ON THE IMAGES THAN SEEN ON RADIOGRAPHS. |                              |  |   |  |



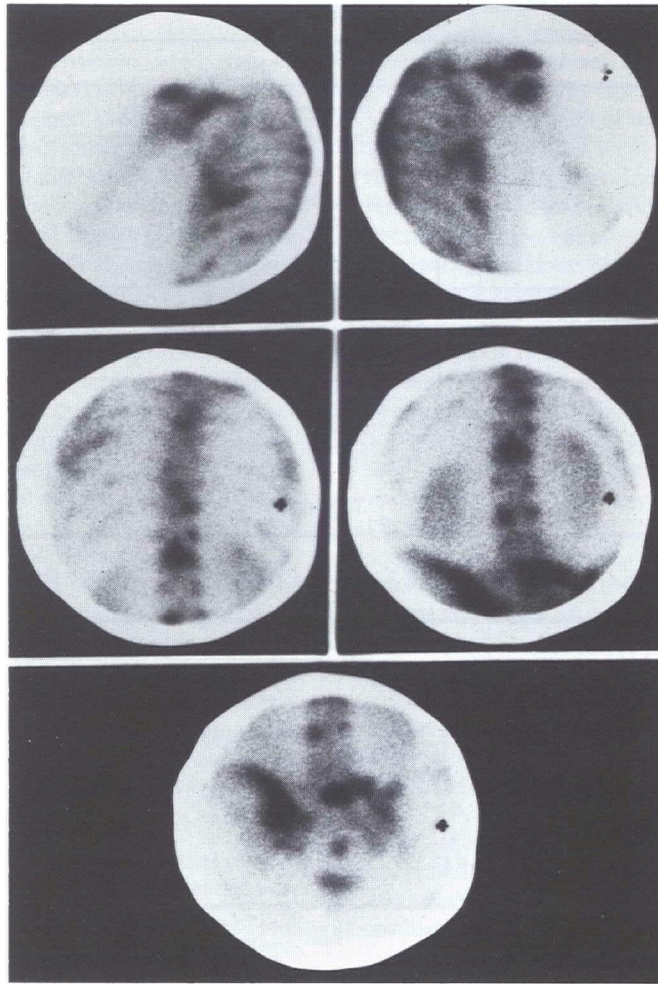


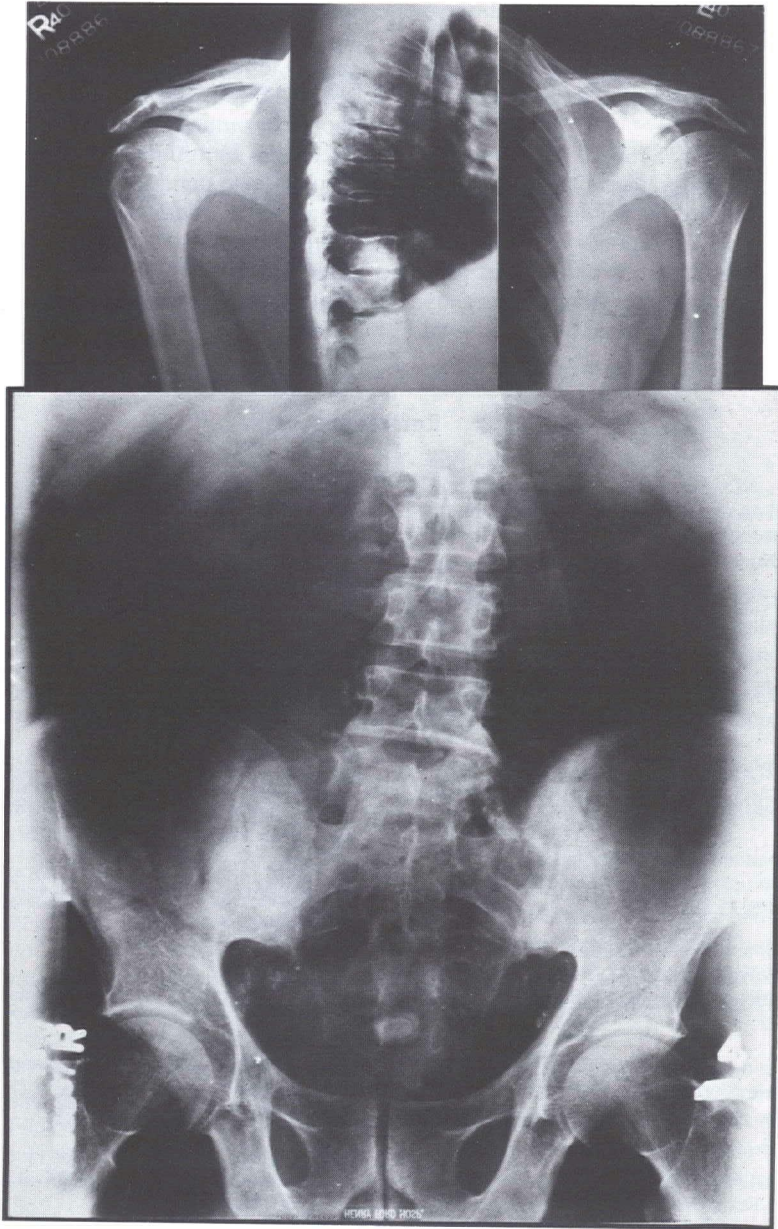
Figure 2a — See legend opposite page

appropriate intervals. If the presence or absence of bone metastases means the difference between curative and palliative treatment, something more immediate must be done. In some cases, laminography will reveal the lesion,<sup>12</sup> and confirm the diagnosis. In accessible areas, bone biopsy should be considered. If tumor is found, the diagnosis is secure. One should be cautious of negative results, however, as small lesions can be missed at the time of biopsy. Should there be any doubt, a repeat bone image may reveal whether or not the appropriate area

has been sampled. It is also possible to localize the area by radionuclide imaging and mark the overlying skin surface.

Solitary areas of abnormality should also be considered as possible metastases. One recent report<sup>15</sup> states that 54% of 100 single lesions reviewed were found to be metastatic disease. The report covered various tumors, four of which were prostate. In this same report, the authors found that a solitary lesion accounted for 11% of their abnormal images. The finding of a single metastasis is a

## Radionuclide Bone Imaging



Figures 2a and 2b

This patient is a 50-year-old man with cancer of the prostate whose images (a) opposite page show diffuse areas of increased activity, while radiographs (b) fail to reveal any specific abnormality (selected areas; other views were also unremarkable). This combination of appearances is characteristic of metastatic disease.



## Marks and Eyler

contra-indication to curative treatment, even if within the radiotherapy field used in prostatic cancer. Other lesions will become apparent with time in most cases.

As previously mentioned, false negative studies are uncommon and there were none in our series. Moreover, some causes of false negative results in patients with uniform, diffuse disease (and thus diffuse, but relatively equal increased activity) have recently come to light.<sup>16</sup> Diminished or absent renal

uptake of the radionuclide may be a clue to this phenomenon.<sup>17</sup> These patients will have radiographic evidence of their disease. False positive results (due to benign conditions) should be virtually eliminated by reviewing the images with current radiographs in hand. Some benign conditions reveal themselves by a typical radionuclide appearance or distribution. Rarely, bone metastases may present as a negative or "cold" area<sup>18</sup> but we are not aware of any such findings in carcinoma of the prostate.

## References

1. Charkes ND, Sklaroff DM, and Young I: A Clinical Analysis of Strontium Bone Scanning for Detection of Metastatic Cancer, *Amer J Roent* **96**, 647-656
2. Galsko CSB: The Pathological Basis for Skeletal Scintigraphy, *Proc Brit Inst Radiol* **48**, 72-73
3. Merrick MV: Review Article: Bone Scanning, *Brit J Radiol* **48**, 327-351
4. Pendergrass HP, Potsaid MS, and Castronoro FP: The Clinical Use of <sup>99m</sup>Tc Diphosphonate (HEDSPA), *Radiol* **107**, 557-562
5. Subramahian G and McAfee JG: A New Complex of <sup>99m</sup>Tc for Skeletal Imaging, *Radiol* **99**, 192-196
6. Barrett JJ and Smith PHS: Bone Imaging with <sup>99m</sup>Tc Polyphosphate: A Comparison with <sup>18</sup>F and Skeletal Radiography, *Brit J Radiol* **47**, 387-392
7. Silberstein EB et al: Imaging of Bone Metastases with <sup>99m</sup>Tc-SB EDHP (Diphosphonate), <sup>18</sup>F, and Skeletal Radiography, *Radiol* **107**, 551-555
8. Farber DD et al: An Evaluation of the Strontium 85 Scan for the Detection and Localization of Bone Metastases from Prostatic Carcinoma: A Preliminary Report of 93 Cases, *J Urol* **97**, 526-532
9. Roy RR et al: 18 Fluorine Total Body Scans in Patients with Carcinoma of the Prostate, *Brit J Urol* **43**, 58-64
10. Briggs RC: Detection of Osseous Metastases, Evaluation of Bone Scanning with <sup>85</sup>Sr, *Cancer* **20**, 392-395
11. Milner TH et al: Evaluation of Strontium 85 Bone Scans and Roentgenograms in 100 Patients, *Arch Surg* **103**, 371-372
12. Shirazy PH, Rayudu GVS, and Fordham FW: <sup>18</sup>F Bone Scanning: Review of Indications and Results of 1500 Scans, *Radiol* **112**, 361-368
13. Thrall JH et al: Pitfalls in Tc<sup>99m</sup> Polyphosphate Skeletal Imaging, *Amer J Roent* **121**, 739-747
14. Williams DF, Bland WH, and Wetteraw L: Radioactive Fluorine 28 Photoscanning: A Diagnostic Evaluation in Carcinoma of the Prostate, *J Urol* **100**, 675-679
15. Shirazu PH, et al: Review of Solitary <sup>18</sup>F Bone Scan Lesions, *Radiol* **112**, 369-372
16. Thrupkaew AK, Henkin RE and Quinn JL: False Negative Bone Scans in Disseminated Metastatic Disease, *Radiol* **113**, 383-386
17. Sy WM, Patel D and Faunce H: Significance of Absent or Faint Kidney Sign on Bone Scan, *J Nucl Med* **16**, 454-456
18. Goergen TG et al: Cold Bone Lesions: A Newly Recognized Phenomenon of Bone Imaging, *J Nucl Med* **15**, 1120-1124